

Bioactive Glass as a Bone Substitute for Spinal Fusion in Adolescent Idiopathic Scoliosis

A Comparative Study With Iliac Crest Autograft

Brice Ilharreborde, MD, Etienne Morel, MD, Franck Fitoussi, MD, Ana Presedo, MD, Philippe Souchet, MD, Georges-François Penneçot, MD, and Keyvan Mazda, MD

Background: Iliac crest autograft is currently the gold standard material for spinal fusion. However, its use is limited by additional operative time, increased blood loss, and morbidity. Recently, a synthetic osteoconductive bone graft material composed of bioactive glass has been described, with high effectiveness in animal models. Its ability to achieve spinal fusion in human has never been reported. The aim of this study was to compare bioactive glass and iliac crest autograft as bone substitutes in the treatment thoracic adolescent idiopathic scoliosis (AIS).

Methods: Eighty-eight consecutive patients underwent posterior spinal fusion for progressive thoracic AIS. There were 2 study groups based on the type of bone graft used: iliac crest autograft (n = 40) or bioglass (n = 48). A minimum 2-year follow-up was required. Medical data and radiographs were retrospectively analyzed and compared using unpaired *t* test and Mann-Whitney *U* test.

Results: Mean follow-up was 40 months in the autograft group and 38 months in the bioglass group. In the autograft group, there were 2 infections (5%) and 3 mechanical failures (7.5%). One infection (2%) and 1 early mechanical failure (2%) occurred in the bioglass group. Loss of correction of the main thoracic curve between immediate postoperative and latest follow-up averaged 15.5% for autograft group and 11% for the bioglass group ($P = 0.025$). The mean (\pm SD) gain of frontal balance between immediate postoperative latest follow-up was 0.8 (\pm 9.3) mm in the autograft group and 8.1 (\pm 12) mm for the bioglass group ($P = 0.005$).

Conclusions: Results of this retrospective study suggest that bioglass is as effective as iliac crest graft to achieve fusion and maintain correction in AIS. Less complications were seen in the bioactive glass group, but the difference did not reach statistical significance. Bioactive glass can be proposed in the treatment of AIS, avoiding the morbidity of iliac crest harvesting. However, clinical and radiological outcomes need to be confirmed at long-term follow-up.

Level of Evidence: Level III

Key Words: spine, adolescent idiopathic scoliosis, bone substitute, bioglass

(*J Pediatr Orthop* 2008;28:347–351)

From the Department of Pediatric Orthopedics, Robert Debré Hospital, Paris, France.

None of the authors received financial support for this study.

Reprints: Brice Ilharreborde, MD, Department of Pediatric Orthopedics, Robert Debré Hospital, 48 Bd Sérurier 75019 Paris, France. E-mail: i_brice@hotmail.com.

Copyright © 2008 by Lippincott Williams & Wilkins

The goal of scoliosis surgery is, first, to correct the deformity and, second, to achieve solid fusion of the correction obtained. The healing response of the spinal fusion is influenced by many variables, including host site conditions (decortication procedure, level of fusion, local blood supply), mechanical environment (instrumentation, stability), and graft bone conditions (source, type, amount of bone).¹ Currently, autogenous cancellous bone is the gold standard bone grafting material for spinal fusion. The most common site for harvesting autograft is the iliac crest. However, the use of autogenous bone graft is limited by the additional surgical time required to harvest the graft, the increased blood loss, the morbidity associated with the donor site, and the limited availability of cancellous bone. Bone graft substitutes are an alternative technique to enhance fusion rates.

A variety of bone graft substitutes are currently used in orthopaedic surgery including allograft bone, bioactive ceramic granules, beta-tricalcium phosphate, coralline hydroxyapatite, and osteogenic protein-1, with variable fusion success rates.^{1–4} In periodontology, use of a synthetic resorbable osteoconductive bone graft material composed of bioactive glass has recently been described, with high effectiveness in the treatment of intrabony defects.⁵ Similarly, the material provided satisfactory bone healing in feline femoral defects.⁶ To our knowledge, the ability of bioactive glass to achieve fusion in human spinal surgery has never been investigated. The purpose of this clinical and radiological study was to compare the effectiveness of bioactive glass and iliac crest autograft in the treatment of thoracic adolescent idiopathic scoliosis (AIS).

METHODS

Eighty-eight consecutive patients underwent posterior spinal fusion for progressive AIS between February 1998 and November 2003. All surgeries were performed by the same surgeon using the same instrumentation (SCS, EuroSurgical, 62217 Beaurains, France). The surgeon was assisted by a pediatric orthopaedic fellow. Segmental fixation with hybrid instrumentation (ie, pedicle screws at lumbar levels and hooks at thoracic levels) was used in all cases. In case of stiff thoracic curve (ie, reducibility under 50% on preoperative traction radiograph or supine bending films) or major loss of thoracic kyphosis (ie, thoracic kyphosis under 15 degrees), anterior release through thoracoscopy was performed first. During that procedure, the apex of the deformity and 2 disks above and below that level were released. No bone graft was used for

fusion. Thoracoplasty was associated in all cases, but the bone from thoracoplasty was not kept for posterior fusion.

Posterior fusion was performed 3 or 4 days later. During the posterior procedures, spinal cord function was monitored by means of somatosensory/motor-evoked potentials, but no Stagnara wake-up test was used. Autotransfusion was performed with blood collected both preoperatively and intraoperatively.

The study patients were divided into 2 groups based on the type of bone graft used. The method of grafting depended only on when the patient was referred and the type of graft used at that time. We retrospectively studied the sequential use of 2 methods of bone grafting. Patients operated on between January 1998 and April 2001 received autograft harvested from the iliac crest, whereas those operated on from May 2001 to December 2003 received 15 cm³ of bioglass (Novabone, Novabone Products, Alachua, Fla) hydrated by the patient's blood (Fig. 1).

With the patient in a prone position, a midline longitudinal incision was made. The vertebrae to be fused were identified, and subperiosteal exposure was performed to the tips of the transverse processes. Facet joints were excised, and the transverse processes and laminae were decorticated. After decortication and instrumentation, local autograft with or without bioglass was added. The graft materials were placed in the decorticated area in the same manner in both groups.

After surgery, patients were allowed a gradual return to full activity without external bracing except when thoracoplasty had been associated. Physical therapy was initiated on postoperative day 2 to begin early mobilization and ambulation. Intraoperative and postoperative complications were recorded.

Postoperative follow-up for a minimum of 2 years was required for inclusion in the study. All patients had standing

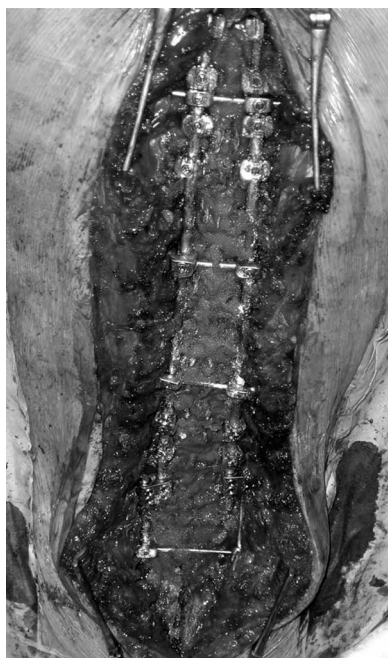

FIGURE 1. Intraoperative view of bioglass, associated to local autograft.

TABLE 1. Demographics of Autograft Versus Bioactive Glass Group

	Autograft (n = 40)	Bioactive Glass (n = 48)
Sex	7 males/33 females	11 males/37 females
Age (mean ± SD), y	14.8 ± 1.6	15.2 ± 1.6
Follow-up (mean ± SD), mo	40 ± 15.8	38 ± 10.3

full-length anteroposterior and lateral radiographs of the spine obtained before surgery, immediately after surgery, and at subsequent follow-up visits. In addition, supine bending films, traction radiographs, or both were performed preoperatively to assess curve reducibility.

The stability and success of spinal fusion were assessed by history, examination, and radiography. Radiographic parameters included Cobb angle of the main thoracic curve, main thoracic curve reducibility, curve type according to King's and Lenke's classifications, frontal balance (distance in millimeters between the center of T1 and the center sacral line), and T9 sagittal offset.

Demographic data and preoperative radiographic parameters were compared between the 2 groups using an unpaired *t* test and the Mann-Whitney *U* test. The Cobb angle measurement of the fused segments on the initial postoperative radiograph was compared with the Cobb angle measurement at final follow-up to assess loss of correction. Loss of correction and sagittal balance between immediate postoperative and latest follow-up were compared using an unpaired *t* test and the Mann-Whitney *U* test. A *P* < 0.05 was considered significant.

RESULTS

Demographics of the Study Groups

Among the 88 consecutive AIS operated on, 40 patients received iliac crest autograft and 48 received bioactive glass. No patient was lost to follow-up. Demographics of each group are listed in Table 1. Mean follow-up period was 40 months in the autograft group (range, 24–84 months) and 38 months in the bioactive glass group (range, 25–52 months). No statistical difference was found between the groups.

Preoperative Radiographic Parameters

Preoperative radiographic parameters of the 2 study groups are reported in Table 2. No statistical difference was found in any of the parameters between the 2 groups.

TABLE 2. Preoperative Radiographic Parameters of the 2 Study Groups

	Autograft (n = 40)	Bioactive Glass (n = 48)
Main thoracic Cobb angle (mean ± SD), degrees	55.7 ± 14.4	56.5 ± 19.8
Main thoracic curve reducibility (mean ± SD), %	45.4 ± 16.8	50.7 ± 14.5
Frontal imbalance (mean ± SD), mm	13.6 ± 9.0	14.8 ± 10.9
T9 sagittal offset (mean ± SD), degrees	-6.4 ± 5.4	-6.1 ± 5.8

The distribution of curve type according to King's classification in the autograft group was 2 King I, 5 type II, 16 type III, 8 type IV, and 9 type V. According to Lenke's classification, there were 20 type 1, 15 type 2, no type 3, 4 type 4, no type 5, and 1 type 6. An anterior release before the posterior fusion associated with thoracoplasty was performed in 16 patients.

The distribution of curve type in the bioactive glass group was one King I, 12 King II, 22 King III, 7 King IV, and 6 King V. According to Lenke's classification, there were 22 type 1, 17 type 2, 2 type 3, 2 type 4, 4 type 5, and 1 type 6. Twenty patients required an anterior release before the posterior approach, associated with thoracoplasty.

The number of patients who underwent thoracoplasty and who subsequently had brace postoperatively was not significant between the 2 groups.

Complications

In the autograft group, there were 2 infections (5%) and 3 mechanical failures (7.5%) at the proximal portion of the construct. Bone formation was not assessed by computed tomography, but these 3 pseudarthroses were associated with loss of correction and proximal junctional kyphosis. No mechanical failure was observed at the thoracolumbar junction. One of the latter failures required a revision procedure because of disabling pain and progressive loss of frontal balance. Instrumentation was removed from 2 other patients (5%) who complained of pain. Intraoperative verification revealed that fusion had been achieved with no pseudarthrosis. Three patients (7.5%) still complained of donor site pain at latest follow-up.

One infection (2%) occurred in the bioglass group. One early mechanical failure (2%) was observed and required a revision procedure. The cause was a technical error with initial misplacement of a proximal hook.

Mechanical failures were excluded from the rest of the analysis.

Blood Loss

Blood loss averaged 853 (± 240) mL in the bioglass group and 1280 (± 370) mL in the autograft group. The difference was statistically significant ($P = 0.02$).

Fused Levels, Loss of Correction, Sagittal Balance

The number of levels fused averaged 12.1 (± 1.8) in the autograft group and 11.8 (± 2) in the bioglass group. The difference was not significant. The distal level of fusion in the autograft group was L2 in 16 cases, L3 in 16 cases, and L4

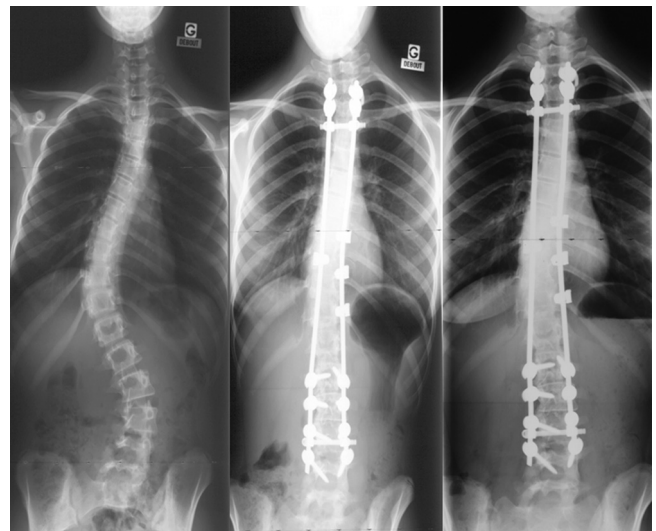


FIGURE 2. Preoperative, immediate postoperative and latest frontal radiographs of a 15-year-old patient who was operated using bioglass. Solid fusion was obtained at 32 months postoperative.

in 8 cases. In the bioglass group, the last instrumented level was L2 in 18 cases, L3 in 19 cases, and L4 in 11 cases. All patients had fusion of the thoracolumbar junction.

Radiographic parameters of the 2 study groups at latest follow-up are presented in Table 3. Loss of correction of the main thoracic curve between immediate postoperative and latest follow-up averaged 15.5% for the autograft group and 11% for the bioglass group (Fig. 2). The difference was statistically significant ($P = 0.025$). The loss of correction averaged 1.9 (± 3.7) degrees in the bioactive glass group and 3.7 (± 3.0) degrees in the autograft group.

At latest follow-up, the T9 sagittal offset was not significantly different between the 2 groups ($P = 0.15$).

DISCUSSION

The results of this study suggest that spinal fusion using bioactive glass as bone substitute to complete local autograft achieves results similar to those obtained using autologous iliac crest bone graft in patients with AIS. In addition, fewer complications and less loss of correction were observed postoperatively in the bioglass group.

Considered the gold standard in spinal fusion, iliac crest bone graft is very effective in augmenting bone healing. In providing osteogenic precursors cells, it is osteoinductive and osteoconductive. However, harvesting of iliac crest graft is associated with numerous complications including bleeding, neurovascular injury, gait disturbance, fracture, pain, and cosmetic problems.^{7,8} Major complications have been reported in 10% and minor complications in 39% of patients who undergo an iliac crest bone graft. Donor site pain is the most common complication, with reported incidence rates as high as 29%.⁹ In a series of children, Skaggs et al¹⁰ reported pain severe enough to interfere with daily activity in 15% at 4-year follow-up. These limitations have led to the use of

TABLE 3. Radiographic Parameters of the 2 Study Groups at Latest Follow-Up

	Autograft (n = 40)	Bioactive Glass (n = 48)
Main thoracic Cobb angle (mean \pm SD), degrees	31.1 \pm 12.5	25.2 \pm 12
Correction (mean \pm SD), %	44.6 \pm 16	55.3 \pm 12.7
Frontal imbalance (mean \pm SD), mm	13.7 \pm 8.5	13.0 \pm 8.3
T9 sagittal offset (mean \pm SD), degrees	-5.8 \pm 3.3	-6.9 \pm 4

different bone graft substitutes, including allograft, composites of bone marrow, and demineralized bone matrix (DBM), and osteogenic protein-1 (OP-1).^{1,11}

Several studies have demonstrated the efficacy of allograft for AIS.^{12,13} However, results are controversial for adult spine fusion, and costs remain high.¹⁴ In addition, banked allograft bone is not often available in our country, and the risk of disease transmission with fresh and fresh-frozen allograft is not negligible.

In contrast to allograft bone, DBM has osteoconductive and osteoinductive properties. In one clinical study in which DBM was used as an isolated graft material, a lower fusion rate was observed compared with that obtained with autologous bone graft.¹⁵ In contrast, stable fusion was achieved in patients operated on for AIS when DBM was associated with bone marrow.¹¹ This difference is probably due to osteogenic precursor cells and growth factors introduced by the addition of bone marrow.¹⁶

Some authors have also reported satisfactory results with synthetic porous ceramic, but this technique is relatively costly.¹⁷

Recently, there has been keen interest in the use of osteoinductive agents, including bone morphogenetic proteins for spinal fusion. OP-1 (or BMP-7) is one such agent and has been shown to speed the rate of bone healing and to improve the performance of autograft in animals.¹⁸ However, few human clinical studies are available. Kanayama et al¹ recently reported that OP-1 reliably induced viable amounts of new bone formation, but their fusion success rate, evaluated by surgical exploration in 7 patients, was only 57%.

The ideal graft material should be biocompatible, bioresorbable, bioconductive, and cost-effective. Bioactive glass is an osteoconductive bone substitute that fulfills these requirements, remodeling to normal bone over time and reducing local inflammatory reactions.^{19,20} Several studies have previously shown that bioglass also exhibits the property of osteostimulation, associated with higher rates of osteoblast activity than hydroxyapatite.^{19,21} Moreover, in studies on oral microorganisms in vitro, bioglass has demonstrated antibacterial properties, which may reduce the potential for bacterial colonization of the sites grafted.²² In animal studies, mixes of autograft and bioactive glass have produced results comparable to those of autograft alone for nonhealing calvarial defects and spinal fusion.^{23,24} However, to our knowledge, the ability of bioactive glass to achieve spinal fusion in humans has never been reported.

It is now accepted that loss of correction after fusion in AIS can occur during a 2-year follow-up period, mainly during the first postoperative year. Results of spine surgery can be reliably evaluated radiologically after a minimum follow-up of 2 years.²⁵ Loss of correction after posterior fusion for AIS using Cotrel–Dubousset or more recent segmental instrumentation varies in the literature between 8% and 28%.²⁶ In the present series, the difference between Cobb angle measurements on immediate postoperative radiographs and at final follow-up averaged 11% in the bioactive glass group and 15.5% in the autograft group. Blood loss was significantly reduced when bioglass was used. Fewer complications were seen in the bioactive glass group, but the difference did not

reach statistical significance, likely due to the small number of cases.

There are several weaknesses in this study. Placement into different study groups was dependent on the type of bone graft being used by the surgeon at that time. Thus, the 2 groups of patients represent a succession in time rather than a randomized study. For that reason, the reduction of blood loss can also be explained by the learning curve of the operating team and the improvement of its technique. All the procedures were performed by a single surgeon, using the same technique for both groups, but the results need to be confirmed in a multicenter study. In addition, the follow-up for the patients was different between the 2 groups. The autograft group had the longest follow-up of 84 months, whereas the bioglass group had follow-up to 52 months. Even though loss of correction mainly occurs during the 2 first postoperative years, one can argue that more pseudarthroses might be reported after longer follow-up. This will need to be further studied at long-term follow-up. Another confounding factor is that although the age at the time of surgery was not different between the 2 groups and that all the patients were operated on after they had their menarche, the exact stage of physiologic maturity at surgery was not investigated. Thus, the eventual role of crankshaft phenomenon in the loss of correction was not evaluated.

In both groups, local autograft was used, mixed with either iliac crest autogenous bone graft or bioactive glass. Violas et al recently showed that in situ local autograft was sufficient to achieve spinal fusion in patients with AIS. They concluded that the association between autograft obtained from spinous processes, laminae and transverse processes, and an adequate fusion technique might obviate the necessity of any additional graft material.²⁷ Thus, the respective roles of bioglass and in situ local autograft are difficult to distinguish in the spinal fusion achieved in the present series.

Results of this study suggest that bioactive glass can be proposed as an effective bone substitute in the treatment of AIS, avoiding iliac crest harvesting and the related morbidity. However, clinical and radiological outcomes warrant longer term follow-up.

REFERENCES

1. Kanayama M, Hashimoto T, Shigenobu K, et al. A prospective randomized study of posterolateral lumbar fusion using osteogenic protein-1 (OP-1) versus local autograft with ceramic bone substitute: emphasis of surgical exploration and histologic assessment. *Spine*. 2006;31(10):1067–1074.
2. Hashimoto T, Shigenobu K, Kanayama M, et al. Clinical results of single-level posterior lumbar interbody fusion using the Brantigan I/F carbon cage filled with a mixture of local morselized bone and bioactive ceramic granules. *Spine*. 2002;27(3):258–262.
3. Muschik M, Ludwig R, Halbhüner S, et al. Beta-tricalcium phosphate as a bone substitute for dorsal spinal fusion in adolescent idiopathic scoliosis: preliminary results of a prospective clinical study. *Eur Spine J*. 2001;10 Suppl 2:S178–S184.
4. Thalgott JS, Giuffre JM, Fritts K, et al. Instrumented posterolateral lumbar fusion using coralline hydroxyapatite with or without demineralized bone matrix, as an adjunct to autologous bone. *Spine J*. 2001;1(2):131–137.
5. Mengel R, Schreiber D, Flores-de-Jacoby L. Bioabsorbable membrane and bioactive glass in the treatment of intrabony defects in patients with generalized aggressive periodontitis: results of a 5-year clinical and radiological study. *J Periodontol*. 2006;77(10):1781–1787.

6. Dorea HC, McLaughlin RM, Cantwell HD, et al. Evaluation of healing in feline femoral defects filled with cancellous autograft, cancellous allograft or Bioglass. *Vet Comp Orthop Traumatol*. 2005;18(3):157–168.
7. Banwart JC, Asher MA, Hassanein RS. Iliac crest bone graft harvest donor site morbidity. A statistical evaluation. *Spine*. 1995;20(9):1055–1060.
8. Robertson PA, Wray AC. Natural history of posterior iliac crest bone graft donation for spinal surgery: a prospective analysis of morbidity. *Spine*. 2001;26(13):1473–1476.
9. Fernyhough JC, Schimandle JJ, Weigel MC, et al. Chronic donor site pain complicating bone graft harvesting from the posterior iliac crest for spinal fusion. *Spine*. 1992;17(12):1474–1480.
10. Skaggs DL, Samuelson MA, Hale JM, et al. Complications of posterior iliac crest bone grafting in spine surgery in children. *Spine*. 2000;25(18):2400–2402.
11. Price CT, Connolly JF, Carantzas AC, et al. Comparison of bone grafts for posterior spinal fusion in adolescent idiopathic scoliosis. *Spine*. 2003;28(8):793–798.
12. Blanco JS, Sears CJ. Allograft bone use during instrumentation and fusion in the treatment of adolescent idiopathic scoliosis. *Spine*. 1997;22(12):1338–1342.
13. Fabry G. Allograft versus autograft bone in idiopathic scoliosis surgery: a multivariate statistical analysis. *J Pediatr Orthop*. 1991;11(4):465–468.
14. An HS, Lynch K, Toth J. Prospective comparison of autograft vs. allograft for adult posterolateral lumbar spine fusion: differences among freeze-dried, frozen, and mixed grafts. *J Spinal Disord*. 1995;8(2):131–135.
15. Cook SD, Dalton JE, Prewett AB, et al. In vivo evaluation of demineralized bone matrix as a bone graft substitute for posterior spinal fusion. *Spine*. 1995;20(8):877–886.
16. Goldberg VM. Bone grafts and their substitutes: facts, fiction, and futures. *Orthopedics*. 2001;24(9):875–876.
17. Delecrin J, Takahashi S, Gouin F, et al. A synthetic porous ceramic as a bone graft substitute in the surgical management of scoliosis: a prospective, randomized study. *Spine*. 2000;25(5):563–569.
18. Cook SD, Wolfe MW, Salkeld SL, et al. Effect of recombinant human osteogenic protein-1 on healing of segmental defects in non-human primates. *J Bone Joint Surg Am*. 1995;77(5):734–750.
19. Vrouwenvelder WC, Groot CG, de Groot K. Histological and biochemical evaluation of osteoblasts cultured on bioactive glass, hydroxylapatite, titanium alloy, and stainless steel. *J Biomed Mater Res*. 1993;27(4):465–475.
20. Wilson J, Pigott GH, Schoen FJ, et al. Toxicology and biocompatibility of bioglasses. *J Biomed Mater Res*. 1981;15(6):805–817.
21. Oonishi H, Kushitani S, Yasukawa E, et al. Particulate bioglass compared with hydroxyapatite as a bone graft substitute. *Clin Orthop Relat Res*. 1997;334:316–325.
22. Allan I, Newman H, Wilson M. Antibacterial activity of particulate bioglass against supra- and subgingival bacteria. *Biomaterials*. 2001;22(12):1683–1687.
23. Bergman SA, Litkowski LJ. *Bone In-fill of Non-Healing Calvarial Defects Using Particulate Bioglass and Autogenous Bone*. Bioceramics 8. Paris, France: Elsevier Science; 1995:17–21.
24. Cunningham BW, Oda I, Buckley R, et al. The use of Bioglass for spinal arthrodesis and iliac crest repair—an in vivo sheep model. Proceedings of the North American Spine Society, Annual Meeting, San Francisco, CA, October 28–31. Paris, France: Elsevier Science; 1998:214–216.
25. Remes V, Helenius I, Schlenzka D, et al. Cotrel–Dubousset (CD) or Universal Spine System (USS) instrumentation in adolescent idiopathic scoliosis (AIS): comparison of midterm clinical, functional, and radiologic outcomes. *Spine*. 2004;29(18):2024–2030.
26. Helenius I, Remes V, Yrjonen T, et al. Harrington and Cotrel–Dubousset instrumentation in adolescent idiopathic scoliosis. Long-term functional and radiographic outcomes. *J Bone Joint Surg Am*. 2003;85-A(12):2303–2309.
27. Violas P, Chapuis M, Bracq H. Local autograft bone in the surgical management of adolescent idiopathic scoliosis. *Spine*. 2004;29(2):189–192.